



# Outbreaks of *Sarcocystis* spp. in exotic birds kept in captivity at the Cali Zoo (Colombia): Case series

Ana María Henao Duque<sup>1\*</sup> ; Diana Buitrago G<sup>2</sup> ; Juliana Peña-Stadlin<sup>2</sup> ; Francisco Carvallo C<sup>3</sup>

<sup>1</sup>Zoopath Laboratorio de Patología Veterinaria, Cali, Colombia.

<sup>2</sup>Fundación Zoológica de Cali, Unidad de Bienestar Animal, Cali, Colombia.

<sup>3</sup>Virginia Maryland College of Veterinary Medicine, Blacksburg, Virginia, EE.UU.

\*Correspondencia: [laboratoriozoopath@gmail.com](mailto:laboratoriozoopath@gmail.com)

Received: Marz 2021; Accepted: October 2021; Published: May 2022.

## ABSTRACT

In a 19-month long period there were outbreaks in which 16 exotic birds that belonged to the collection of the Cali Zoo died. Most of the affected animals were Australian parrots, of which a large percentage had sudden death. Mortalities occurred in enclosures with different characteristics, located in exhibition and internal areas of the Zoo. Necropsy, histopathology, and immunohistochemistry were performed in some animals that did not present an advanced state of decomposition, where the presence of a parasitic pneumonia with intraendothelial merozoites of *Sarcocystis* spp. was confirmed. Some of the individuals who survived, received combined antiparasitic, antibiotic, and antifungal therapy. Risk factors and important aspects of the management to prevent Sarcocystosis in animals kept under human care are mentioned, because this disease has high mortality in Old World birds, most of the time, without previous clinical signs.

**Keywords:** Apicomplexa; avian disease; hepatomegaly; sarcocystosis; splenomegaly; zoo animal (Source: MeSH).

## RESUMEN

En un periodo de 19 meses se presentaron brotes en los cuales fallecieron 16 aves exóticas que pertenecían a la colección del Zoológico de Cali. La mayoría de los animales afectados fueron psitácidos australianos, de los cuales un gran porcentaje presentó muerte súbita. Las mortalidades se presentaron en recintos con diferentes características, localizados en zonas de exhibición y áreas internas del zoológico. Se realizó necropsia, histopatología e inmunohistoquímica en algunos animales que no presentaron estado avanzado de descomposición, donde se confirmó la presencia de una neumonía parasitaria con merozoitos de *Sarcocystis* spp. intraendoteliales. Algunos de los individuos que sobrevivieron recibieron una terapia combinada con antiparasitario, antibiótico y antifúngico. Se mencionan factores de riesgo y aspectos importantes en el manejo para prevenir la Sarcocistosis en estos animales mantenidos bajo cuidado humano, debido a que esta enfermedad presenta alta mortalidad en aves del viejo mundo, y a menudo cursa sin signos clínicos previos.

**Palabras clave:** Apicomplexa; animal de zoológico; enfermedad aviar; esplenomegalia; hepatomegalia; sarcosporidiasis (Fuente: MeSH).

### How to cite (Vancouver).

Henao DAM, Buitrago DG, Peña JS, Carvallo F. Outbreaks of *Sarcocystis* spp. in exotic birds kept in captivity at the Cali Zoo (Colombia): Case series. Rev MVZ Córdoba. 2022; 27(2):e2146. <https://doi.org/10.21897/rmvz.2146>



©The Author(s) 2022. This article is distributed under the terms of the Creative Commons Attribution 4.0 International License (<https://creativecommons.org/licenses/by-nc-sa/4.0/>), lets others remix, tweak, and build upon your work non-commercially, as long as they credit you and license their new creations under the identical terms.

## INTRODUCTION

*Sarcocystis* is a genus of protozoan parasites of the Apicomplexa family with a mandatory cycle of two hosts (1,2). Although the species of this genus of parasites are species-specific, *Sarcocystis falcatula* is the most common species in America, affecting multiple species of birds (1,2). The opossum (*Didelphis virginianus*/*D. marsupialis*) is the definitive host (3,4), while passerine birds of the genera *Molothrus* and *Quiscalus* are the intermediate ones, in which schizogony is followed by the formation of subclinical cysts in the muscle, usually macroscopically visible to the naked eye (1). However, other bird species are accidental intermediate hosts (1,5,6,7,8).

The New World psittacidae are usually resistant, with an asymptomatic infection; however, the Old World birds (Australia, Asia, and Africa) —mainly psittacidae, are highly susceptible to the disease, which usually leads to death without previous clinical signs (1,2,9). Mortality in these birds is caused by parasitic pneumonia with systemic spread (2,9), and occasionally, weakness, dyspnea, anorexia, or a neurological condition prior to death (2,10,11). Necropsy findings can be minimal or severe, and pulmonary congestion with edema and hemorrhage, hepatosplenomegaly, myocardial discoloration, and cerebral and meningeal congestion (2,9) are mainly found. Microscopically, there are multiple aggregates of elliptic structures, compatible with merozoites, located in the pulmonary vascular endothelium, which sometimes have a sinuous or elongated shape, like microfilariae (2,9). Merozoites can also be found in lung imprints (2). The other lesions are reflected in vascular and inflammatory changes, such as diffuse pulmonary congestion with hemorrhage, fibrin and edema deposits, perivascular and peribronchial lymphoplasmacytic infiltrates, multifocal random hepatic necrosis of variable extent, with a lymphoplasmacytic infiltrates in the portal and sinusoid areas, severe splenic congestion or histiocytosis in animals surviving the acute phase, myocardial necrosis of variable extension with hemorrhage, and mononuclear infiltrate composed of lymphocytes, plasma cells and macrophages (2,9). Nervous system-related lesions are usually absent, but encephalitis or encephalomalacia may be found (2,9). Muscle cysts occur quickly and mature up to 2 or 3 months after infection (2); however, they must be differentiated from other apicomplexans, such as *Toxoplasma gondii*, using specific molecular techniques (2).

The Cali Zoo is in the Southwestern Colombia, in the Province of Valle del Cauca. It is located in the middle basin of the Cali River. The facilities house approximately 2,500 animals, grouped in 230 species, including amphibians (7%), mammals (21%), reptiles (12%), birds (30%), fish (21%), and butterflies (9%).

This report describes clinical, pathological, and epidemiological aspects of *Sarcocystis* spp.-associated mortality on 16 individuals of the 19 affected ones in the exotic-birds collection of the Cali Zoo, from 2017 to 2019. Eighteen of them belonged to the Psittacidae family and one to Alcedinid.

## Patient Examinations

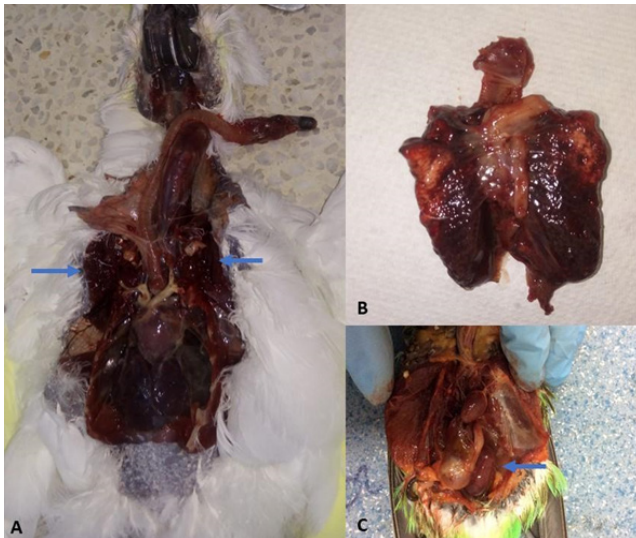
**Case 1. Anamnesis.** In January 2017, an adult sulfur-crested cockatoo (*Cacatua galerita*) —hosted in an external enclosure without public exposure, presented low food consumption and weakness.

**Findings on clinical examination.** Wax peeling, low body condition, diarrhea and tachypnea were found.

**Diagnostic aids.** A coprological examination was performed where only augmented microbiota (bacilli) and urate crystals were found.

**Treatment.** The patient received nonspecific therapy with enrofloxacin, nebulization, and fluid therapy (PO); however, it died the next day and underwent necropsy. The macro and microscopic findings are detailed in Table 1 and Figure 1.

**Case 2. Anamnesis.** Between December 2017 and January 2018, nine adult Budgerigar (*Melopsittacus undulatus*) of the collection died. The animals were in an internal and mixed exhibition with other Australian psittacidae. Seven of the animals were found dead in the compound, without any previous reports of disease. The carcasses presented moderate to severe autolytic changes and loss of feathers at the head level, which led the handlers to suspect of intra/interspecies aggression at the beginning of the mortality phase. Only two individuals were found to be weak and were moved to the Zoo hospital for evaluation.



**Figure 1.** Frequent macroscopic findings. **A** and **B**, the lungs (arrows) of a *Cacatua galerita* showed hemorrhage and severe diffuse congestion. **C**, severe splenomegaly (arrow) in a *Melopsittacus undulatus* is shown.

**Findings on clinical examination.** The two animals evaluated showed nonspecific clinical signs of weakness and were left for observation.

**Diagnostic aids.** A coprological exam was performed in one of the animals and found negative for gastrointestinal parasites.

**Treatment.** Animals were left for observation at the Zoo hospital with oxygen and fluid therapy (PO); however, they died the next day. Necropsy and histopathology were performed in only six of the nine animals that died, due to the decomposition of some corpses (Table 1).

**Case 3. Anamnesis.** In February 2019, an adult lorikeet (*Trichoglossus haematodus*) — hosted in an internal enclosure without no public exposure, was taken to the Zoo hospital because it was reported to be isolated by an intraspecific assault.

**Findings on clinical examination.** The animal presented low body condition, moderate dehydration, random loss of plumage, crusts in the periocular region, and multiple hematomas in the right pectoral and humeral regions.

**Treatment:** It was left for observation at the Zoo hospital with fluid therapy (PO) and analgesics with satisfactory evolution; however, it was found dead 15 days later with no previous clinical signs prior to death (Table 1).

**Case 4. Anamnesis.** In March 2019, an adult Kookaburra (*Dacelo novaeguineae*) —hosted in an external enclosure with two more birds without public exposure, was found dead in the enclosure without previous clinical signs (Table 1).

**Case 5. Anamnesis.** In May 2019, an adult Mitchell cockatoo (*Lophochroa leadbeateri*) — hosted in an internal enclosure, was found dead without previous clinical signs (Table 1).

**Case 6. Anamnesis.** In June 2019, several animals were reported to decay from a mixed internal display of Australian psittacidae (*M. undulatus* and *Nymphicus hollandicus*), in which a previous mortality had occurred (case 2). On June 1<sup>st</sup>, an *M. undulatus* was transferred to the Zoo hospital. The next day, in the same enclosure, four individuals of *N. hollandicus* were depressed; however, due to the conditions of the enclosure, the animals were not able to be captured. Twenty-four hours later, one of them was found dead and the remaining three were captured. After 7 days, an *M. undulatus* was found dead in the enclosure, without previous clinical signs.

**Findings on clinical examination.** The *M. undulatus* presented weakness, bristled plumage, low body condition, and ectoparasites. The *N. hollandicus* had weakness and sneezing.

**Treatment.** Fluid therapy (PO), toltrazuril, trimethoprim-sulfadiazine, immunomodulator, itraconazole, and nebulization (SID) were administered to all animals, also left in observation at the Zoo hospital. The next day, after 10 days of treatment, the first *M. undulatus* died. Necropsy and histopathology were performed in the deceased animals (Table 1 and Figure 1). The three *N. hollandicus* were successfully recovered after 20 days of therapy and moved to their compound.

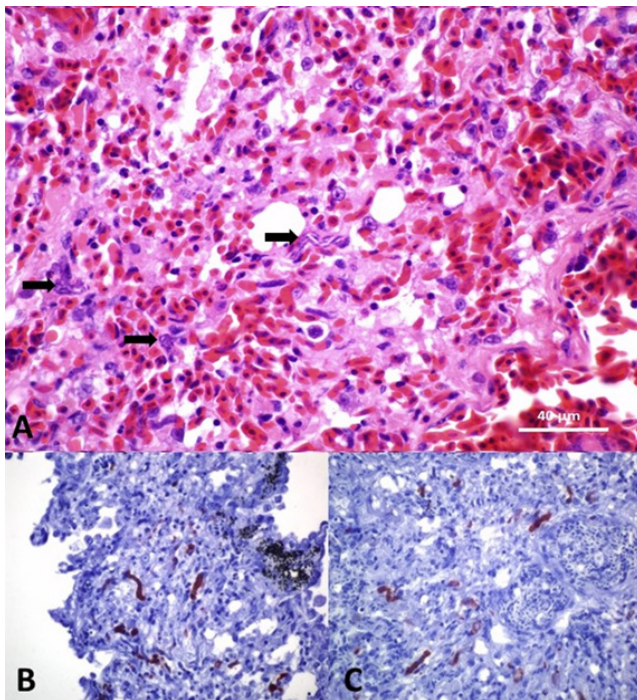
**Specific diagnostic tests.** After the described mortalities, three blocks of tissues embedded in paraffin were sent to the San Bernardino Diagnostic Laboratory, California Animal Health and Food Safety Laboratory, School of Veterinary Medicine, University of California (Davis, USA) to confirm the presumptive diagnosis. A peroxidase-based polymer system was used for the immunohistochemical detection of protozoan antigens. Polyclonal antiserum produced against merozoites, derived from cultures of *Sarcocystis* spp. was used in lung sections from two *M. undulatus* and *C. galerita* (Table 1 and Figure 2).

**Table 1.** Macroscopic and microscopic necropsy findings and other diagnostic tests in the deceased birds.

Case number	Species	Necropsy finding	Histopathological findings	Additional tests
Case 1	<i>Cacatua galerita</i>	Diffuse pulmonary hemorrhage, tracheal and air sac congestion, mild hepatomegaly.	Severe pulmonary edema with hemorrhage and congestion, acute interstitial pneumonia with intraendothelial meronts compatible with <i>Sarcocystis</i> spp. Mild acute multifocal necrotizing hepatitis, acute spleen with intralesional meronts. Other organs with no significant findings.	Positive to IHC by Envision system HRP: <i>Sarcocystis</i> spp. polyclonal antiserum. Positive to fecal occult blood.
Case 2 (6/9 animals diseased)	<i>Melopsittacus undulatus</i>	Low BCS, multifocal to severe diffuse pulmonary congestion with bleeding, mild hepatomegaly and multifocal congestion, intestinal serosa congestion (5/6). Abundant and diffuse whitish material adhered to viscera in the coelomic cavity (1/6).	Severe pulmonary edema with bleeding, congestion, and acute interstitial pneumonia with intraendothelial meronts consistent with <i>Sarcocystis</i> spp. (5/6). Moderate acute multifocal necrotizing hepatitis (3/6). Mild multifocal lymphohistiocytic hepatitis (1/6), histiocytic spleen (3/6), parasitic muscle cysts (1/6), mild chronic multifocal proventriculitis with abundant filamentary structures of <i>Macrorhabdus ornithogaster</i> (1/6). Multifocal to diffuse vascular congestion in brain, cerebellum, lung, and liver (1/6). Other organs without significant findings. Salpingitis and coelomitis by egg yolk (1/6).	Negative to <i>Chlamydophila psittaci</i> qPCR (in an animal sampled postmortem).
Case 3	<i>Trichoglossus haematodus</i>	Low BCS, congestion and moderate multifocal pulmonary edema, multifocal cerebral congestion.	Acute, diffuse, severe pulmonary hemorrhage and congestion, severe lymphoplasmacytic interstitial pneumonia with intraendothelial meronts consistent with <i>Sarcocystis</i> spp. Hepatitis, splenitis and multifocal lymphoplasmacytic myocarditis and a focal parasitic cyst in the myocardium. Other organs without significant findings.	Negative to GI parasites (coprologically).
Case 4	<i>Dacelo novaeguineae</i>	Low BCS, diffuse pulmonary congestion with yellowish foci, severe hepatomegaly, plethoric gallbladder, and multifocal cerebral congestion.	Severe diffuse acute pulmonary congestion and hemorrhage, severe lymphoplasmacytic interstitial pneumonia with intraendothelial meronts consistent with <i>Sarcocystis</i> spp. Parasitic cysts in pectoral, tracheal and myocardial muscle. Multifocal lymphoplasmacytic infiltrates with Mott cells in the muscle, myocardium, brain, liver, and spleen. Mild segmental glomerular hyalinosis.	Negative to <i>Chlamydophila psittaci</i> qPCR. Negative to GI parasites (coprologically).
Case 5	<i>Lophochroa leadbeateri</i>	Mild wax hyperkeratosis, diffuse and severe yellowing of fat, diffuse pulmonary congestion, moderate splenomegaly, liver with coalescing multifocal yellowish foci, plethoric gallbladder, mild cerebral congestion.	Severe acute pulmonary edema with bleeding, congestion, and interstitial pneumonia with intraendothelial meronts ( <i>Sarcocystis</i> spp.). Hepatitis and multifocal lymphoplasmacytic spleen, steatosis, multifocal myocardial degeneration and chronic multifocal pyogranulomatous pansteatitis.	NR
Case 6 (3/6 animals diseased)	<i>Nymphicus hollandicus</i>	Severe diffuse yellowing of adipose tissue, diffuse pulmonary congestion.	Acute, diffuse, severe pulmonary edema with bleeding, congestion, and interstitial pneumonia with intraendothelial meronts ( <i>Sarcocystis</i> spp.). Multifocal lymphoplasmacytic hepatitis and histiocytic spleen.	NR
	<i>Melopsittacus undulatus</i>	Moderate diffuse pulmonary congestion, moderate hepatomegaly, severe splenomegaly.	Severe diffuse pulmonary congestion with edema, bleeding, and interstitial lymphoplasmacytic pneumonia with intraendothelial meronts ( <i>Sarcocystis</i> spp.). Hepatitis, myocarditis, and histiocytic spleen to multifocal lymphoplasmacytic.	
	<i>Melopsittacus undulatus</i>	Low BCS, moderate pulmonary congestion.	Severe diffuse pulmonary congestion with bleeding without evidence of intralesional microorganisms. Multifocal congestion in other organs.	

BCS: Body condition score; IHQ: Immunohistochemistry; HRP: Horseradish peroxidase; qPCR: Real-time polymerase chain reaction; GI: Gastrointestinal; NR: Not reported





**Figure 2.** **A.** Microscopic findings of histological lung sections of a *Cacatua galerita*, showing congestion, edema and numerous intraendothelial meronts (arrows). Hematoxylin-Eosin stain, 400X. **B** and **C**, highlight the positive immunolabeling for *Sarcocystis* spp. in brown color, from lung samples of the same individual. Immunohistochemistry by Envision system horseradish peroxidase (HRP): *Sarcocystis* spp. polyclonal antiserum, 400X.

## DISCUSSION

Sarcocystosis is a common disease in birds, reptiles, and mammals. Parasitic cysts are usually found incidentally in necropsy in the New World birds, rarely associated with lesions or clinical signs (2,6). When the disease occurs, animals present weakness, dyspnea, anorexia, and neurological signs (2,10). Some of these signs were observed in only seven of the 19 affected animals of this report. In Old World birds, there is a great susceptibility and high mortality, especially in psittacidae (8,9). Outbreaks have been reported in zoos of the United States (11,12) and Brazil (4,13), with findings similar to those observed in the 16 exotic birds of this report, of which 15 were psittacidae, and only one, coraciiformes. For the last-mentioned species, there is not available literature reporting the natural infection by *Sarcocystis* spp., which could explain the fatal outcome.

Although sarcocystosis usually has a peracute course in Old World birds, some individuals with clinical signs can survive the acute phase, as evidenced in the three *N. hollandicus* of the present report. Such facts will depend on the ingested parasitic dose, exposure time, and other factors that are difficult to control under natural infection conditions (2,7,9). Experimental infection by *M. undulatus* causes death 2 weeks after (especially between 8 and 11 days post infection) and a low percentage of the individuals survive the infection and develop muscle cysts (1,7).

This report describes two large outbreaks in the same indoor exhibit enclosure. The first in late 2017 and early 2018 and the other one in the second quarter of 2019. In the first outbreak, mortality occurred only in animals in this specific type of enclosure, where the risk of infection is possibly related to the admission of opossums or exposure to their feces, in addition to the presence of cockroaches that might behave as paratenic hosts (14). Although in the mortalities described in the United States and Brazil Zoos due to this infectious agent, several opossums found in areas surrounding the enclosures affected by the outbreaks were slaughtered (4,12), in the Cali Zoo this control measure was not considered. In this respect, capture and relocation of the opossums—which has been reported as effective control measure in an outbreak in the USA (12), was carried out. During the mortality period, necropsy and histopathological evaluation were performed on three adult free-living opossums (*D. marsupialis*), which died naturally for various reasons, in which no sporocysts were observed in the intestine.

In the second outbreak (2019), not only was this exhibition enclosure affected, but randomly others of different characteristics, substrates, and locations within the Zoo, where the only common factor—other than water, was the food preparation area. The latter is considered as a very important aspect since, during the outbreak, the kitchen was in a process of restructuring, a factor that affected the biosecurity and food storage measures, a condition that could favor the entry of paratenic hosts. The substrate has also been described as a potential source of contagion in internal enclosures (8,10). However, only the animals in case 1 and case 4 were in enclosures with soil as substrate that had not been changed recently, being the reason why this factor was not considered in the contagion spectrum.

The *antemortem* diagnosis is based on clinical findings and epidemiological history, since diagnostic tests are not standardized, nor available, and the acute course of the disease leads to death rapidly (1,10). Finally, the importance of confirming the *postmortem* diagnosis and differentiating the agent from other apicomplexans through immunohistochemistry or molecular techniques such as PCR (11), should be highlighted, since in the case of *C. galerita* (case 1), its death coincided with an outbreak of toxoplasmosis that occurred in macropods housed in a nearby enclosure; and therefore, it was initially considered the infection by *Toxoplasma gondii*, which, at the end, was ruled out with immunohistochemistry.

The treatments applied were not successful in the animals of this report, mainly due to the state of deterioration in which they were received at the Zoo hospital, and, in most cases, it was not possible to stabilize them medically. Although some prophylactic treatments were performed on the group of birds affected by the outbreaks, there was no apparent reduction in the occurrence of new cases. After reviewing the medical protocol proposed by the Philadelphia Zoo (11), trimethoprim-sulfadiazine was added to the therapy and the dose and duration of the antiprotozoal toltrazuril was increased, which was an effective therapeutic approach, in at least two birds.

In conclusion, keeping animals in captivity carries with the responsibility to provide their care and to know in depth the pathogens that may affect such populations. Even though *Sarcocystis* spp. in Colombia is usually found incidentally in native or endemic birds, the collections that possess Old World birds must work continuously in the control of risk factors to prevent the spread of infection, considering that it is a life-threatening disease in these species, which often occurs without previous clinical signs, leading to a complex *antemortem* diagnosis. In addition, limiting the entry of opossums, carrying out pest control, and substrate management are the most effective actions to control *Sarcocystis* spp. and other infectious agents of importance.

### Conflict of interests

The authors declare that they have no conflict of interest.

### Acknowledgments

To the San Bernardino Diagnostic Laboratory, California Animal Health and Food Safety Laboratory, School of Veterinary Medicine, University of California (Davis, USA) for their support for immunohistochemical diagnostics.

## REFERENCES

- Box D, Smith JH. The Intermediate Host Spectrum in a *Sarcocystis* Species of Birds. J. Parasitol. 1982; 68(4):668-673. <http://www.jstor.org/stable/3280926>
- Schmidt RE, Reavill D, Phalen D. Pathology of Pet and Aviary Birds. 2<sup>nd</sup> ed. Iowa: Jhon Wiley & Sons, Inc.; 2015.
- Duszynski DW, Box D. The Opossum (*Didelphis virginiana*) as a Host for *Sarcocystis debonei* from Cowbirds (*Molothrus ater*) and Grackles (*Cassidix mexicanus*, *Quiscalus quiscula*). J Parasitol. 1978; 64(2):326-329. <http://www.jstor.org/stable/3279685>
- Godoy SN, De Paula CD, Cubas ZS, Matushima ER, Catão-Dias JL. Occurrence of *Sarcocystis falcatula* in Captive Psittacine Birds in Brazil. J Avian Med Surg. 2009; 23(1):18-23. <http://dx.doi.org/10.1647/2008-006R.1>
- Box D, Duszynski DW. Experimental Transmission of *Sarcocystis* from Icterid Birds to Sparrows and Canaries by Sporocysts from the Opossum. J Parasitol. 1978; 64(4):682-688. <http://www.jstor.org/stable/3279960>
- Crawley RR, Ernst JV, Milton JL. *Sarcocystis* in a Bald Eagle (*Haliaeetus leucocephalus*). J Wildl Dis. 1982; 18(2):253-55. <https://doi.org/10.7589/0090-3558-18.2.253>

7. Marsh AE, Barr BC, Tell L, Koski M, Greiner E, Dame J, Conrad PA. *In vitro* Cultivation and Experimental Inoculation of *Sarcocystis falcatula* and *Sarcocystis neurona* Merozoites into Budgerigars (*Melopsittacus undulatus*). J Parasitol. 1997; 83(6):1189-1192. <http://www.jstor.org/stable/3284386>
8. Suedmeyer WK, Bermudez AJ, Barr BC, Marsh AE. Acute Pulmonary *Sarcocystis falcatula*-like Infection in Three Victoria Crowned Pigeons (*Goura victoria*) Housed Indoors. J. Zoo Wildl. Med. 2001; 3(2):252-356. [http://dx.doi.org/10.1638/1042-7260\(2001\)032\[0252:APSFLI\]2.0.CO;2](http://dx.doi.org/10.1638/1042-7260(2001)032[0252:APSFLI]2.0.CO;2)
9. Reavill DR, Dorrestein G. Psittacines, Coliiformes, Musophagiformes, Cuculiformes. En: Terio KA, McAloose D and St. Leger J, editors. Pathology of Wildlife and Zoo Animals. San Diego: Elsevier; 2018.
10. Siegal-Willott JL, Nietfeld J. Encephalitis Caused by *Sarcocystis falcatula*-like Organisms in a White Cockatoo (*Cacatua alba*). J Avian Med Surg. 2005; 19(1):19-24. <http://dx.doi.org/10.1647/2004-005>
11. Verma SK, Trupkiewicz JG, Georoff T, Dubey JP. Molecularly Confirmed Acute, Fatal *Sarcocystis falcatula* Infection in the Rainbow Lorikeets (*Trichoglossus moluccanus*) at the Philadelphia Zoo J Parasitol. 2018; 104(6):710-712. <http://dx.doi.org/10.1645/18-78>
12. Hillyer EV, Anderson MP, Greiner EC, Atkinson CT, Frenkel JK. An Outbreak of *Sarcocystis* in a Collection of Psittacines. J Zoo Wildl Med. 1991; 22(4):434-445. <http://www.jstor.org/stable/20095186>
13. Ecco R, Luppi MM, Malta MCC, Araújo MR, Guedes RMC, Shivaprasad HL. An Outbreak of Sarcocystosis in Psittacines and a Pigeon in a Zoological Collection in Brazil. Avian Dis. 2008; 52:706-710. <http://dx.doi.org/10.1637/1933-5334-3.4.e43>
14. Clubb SL, Frenkel JK. *Sarcocystis falcatula* of opossums: transmission by cockroaches with fatal pulmonary disease in psittacine birds. J Parasitol. 1992; 78(1):116-124. <http://www.jstor.org/stable/3283697>