



Ureterolithiasis, ureteral torsion and hydronephrosis in a dog

Victor Reis Galindo¹ ; Igor Cezar Kniphoff da Cruz^{2*} ; Rafael Kretzer Carneiro³ ;
Saulo Tadeu Lemos Pinto Filho¹ ; Lícia Flávia Silva Herculano¹ ; Tainara Moraes Pereira³ ;
Rafael Almeida Figuera¹ ; Luiz Paulo Nogueira Aires³ ; Eduarda Mazzardo Bortoluzzi⁴ ;
Ricardo Pozzobon¹ ; Marcus Antônio Rossi Feliciano⁵

¹Universidade Federal de Santa Maria, Cidade Universitária, bairro Camobi, Santa Maria, Brazil.

²Universidade Federal do Espírito Santo, Alto Universitário, S/N, bairro Guararema, Alegre, Brazil.

³Universidade Estadual Paulista "Júlio de Mesquita Filho", Faculdade de Ciências Agrárias e Veterinárias, Departamento de Cirurgia, Via de acesso Prof. Paulo Donato Castellane, s/n, Jaboticabal, Brazil.

⁴Kansas State University, 1530 Mid-Campus Dr., KS 66506, Manhattan, United States.

⁵Universidade de São Paulo, rua Duque de Caxias, 225, bairro Jardim Elite, Pirassununga, Brazil.

*Correspondence: igorcezar.cruz@gmail.com

Received: May 2021; Accepted: December 2021; Published: May 2022.

ABSTRACT

Objective. The objective of the present report was to describe clinical, ultrasonographic, and surgical findings, as well as the therapeutic choice, of a rare case of canine ureteral torsion associated with hydronephrosis and unilateral ureterolithiasis. **Patient evaluation.** A 9-year-old female dog was seen with a history of swelling in the ear region and a tumor in the mammary gland number five of the right chain. In the ultrasound examination for tumor staging, abnormalities were seen in the kidney and left ureter. Pelvic and ureteral dilation, sediment, and diverticular structure in the ureter were abnormal findings. The clinical manifestations were not specific to the urinary tract and were not suggestive of the observed ultrasound abnormalities. An exploratory laparotomy was performed and confirmed the suspected ultrasound diagnosis. In addition, it was possible to identify two twisted ureteral segments. Left unilateral nephrectomy was performed to correct the ureterolithiasis and ureteral torsion. At 15 days postoperatively, no urinary or laboratory changes were identified. **Conclusions.** Because it was possible to verify the abnormalities in the left ureter and kidney before the development of clinical signs, it was possible to institute the appropriate therapy promptly and prevent the disease progression.

Keywords: Stenosis; canine; urinary; kidney; obstruction (*Source: MeSH*).

RESÚMEN

Objetivo. El objetivo de este informe fue describir los hallazgos clínicos, ecográficos y quirúrgicos, así como la terapia instituida, en un caso raro de torsión ureteral asociada a hidronefrosis y ureterolitiasis unilateral en un perro. **Evaluación del paciente.** Una perra de 9 años fue atendida

How to cite (Vancouver).

Reis GV, Kniphoff da CIC, Kretzer CR, Pinto FST, Silva HLF, Moraes PT, et al. Ureterolithiasis, ureteral torsion, and hydronephrosis in a dog. Rev MVZ Córdoba. 2022; 27(2):e2397. <https://doi.org/10.21897/rmvz.2397>



©The Author(s) 2022. This article is distributed under the terms of the Creative Commons Attribution 4.0 International License (<https://creativecommons.org/licenses/by-nc-sa/4.0/>), lets others remix, tweak, and build upon your work non-commercially, as long as they credit you and license their new creations under the identical terms.

con antecedentes de hinchazón en la región de la oreja y un tumor en la glándula mamaria número 5 de la cadena derecha. Durante el examen de ultrasonido para la estadificación del tumor, se observaron cambios en el riñón y el uréter izquierdo, como dilatación pélvica y ureteral, sedimento y estructura diverticular en el uréter. Las manifestaciones clínicas no fueron específicas del tracto urinario y no sugirieron estos cambios. Se realizó una laparotomía exploratoria que confirmó el diagnóstico ecográfico de sospecha y permitió identificar dos segmentos ureterales torcidos. Se realizó nefrectomía unilateral izquierda y, a los 15 días del postoperatorio, no se identificaron alteraciones urinarias ni de laboratorio. **Conclusiones.** Así, fue posible verificar los cambios en el uréter y riñón izquierdos antes del desarrollo de los signos clínicos, lo que permitió instituir la terapia adecuada de manera oportuna y prevenir la progresión de la enfermedad.

Palabras clave: Estenosis; canina; urinaria; renal; obstrucción (*Fuente: MeSH*).

INTRODUCTION

Ureteral stenosis (UE) is a rare urological condition that leads to restricted urinary flow culminating in hydronephrosis and proximal hydroureter (1). Humans with UE have a predisposition for stones formation due to obstruction of the renal collecting system, which delays the crystalline aggregates washing causing nucleation, crystal growth, aggregation, and finally, the development of calculus (2).

Stenosis can be diagnosed based on evidence of hydronephrosis and severe ureteral dilation during ultrasound examination (3), however, a definitive diagnosis is made by magnetic resonance imaging and contrasted examinations (1). In veterinary, torsions in different organs have been described (4,5) and were characterized as a severe complication that requires rapid approach to prevent death of the patient (4).

Regarding the urinary system of small animals, reports of torsions are only related to the urinary bladder (4), and no description of ureters torsions were found. Thus, the objective of this report is to describe an unprecedented case of ureteral torsion in an adult canine.

PATIENT EVALUATION

Anamnesis. A 9-years-old female non-castrated, mixed breed dog (body weight 11.3 kg) was referred with the main complaint of increased volume in the right ear associated with severe itching for approximately five days. In addition, an increase in volume in the mammary chains was reported, but the time of evolution was not informed.

Clinical examination findings. Upon general physical examination, vital parameters were within the normal range for the species. However, a structure with multiple nodules of firm consistency, not ulcerated in the mammary gland number 5 of the right chain was found. The otological examination was performed, and the right ear was enlarged and with fluid content.

Clinical suspicion. The clinical suspicions were otohematoma of the right ear and breast cancer.

Laboratorial, radiographic and ultrasonographic exams. Complete blood count, biochemical analyzes (creatinine, urea, ALT, FA, total proteins, and albumin – Table 1), fine needle aspiration cytology of breast nodules, and imaging tests (chest radiography and abdominal ultrasound exam) were requested. No changes were observed in blood tests, while cytology suggested malignant breast cancer of epithelial origin.

Table 1. Biochemical analysis of a dog with ureterolithiasis and ureteral torsion without clinical symptoms.

Biochemical	Result	Reference
Albumin (g/dL)	3.5	3.2 – 4.1
ALT (UI/L)	29.0	17.0 – 95.0
Creatinine (mg/dL)	0.9	0.6 – 1.4
Alkaline phosphatase (UI/L)	26.0	7.0 – 115.0
Total proteins (g/dL)	5.6	5.5 – 7.2
Urea (mg/dL)	21.0	9.0 – 26.0

ALT – alanine aminotransferase.

No radiographic alterations were found. The ultrasound examination was performed with Logiq F6® (GE Healthcare, Chicago, IL) and linear transducer with a frequency of 7.5MHz. The left kidney measured 5.27 x 4.16 cm in its long axis, with loss of normal renal architecture and lack of corticomedullary distinction. A marked dilation renal pelvis had with the presence of anechogenic content, and moderate amount of hyperechogenic sediment (Figure 1A) was observed. The left ureter was visualized in the usual topography, measuring 1.65 cm in diameter with intraluminal content similar to that found in the renal pelvis. Therefore, ultrasonographic findings suggested hydronephrosis associated with left ureteral dilation.

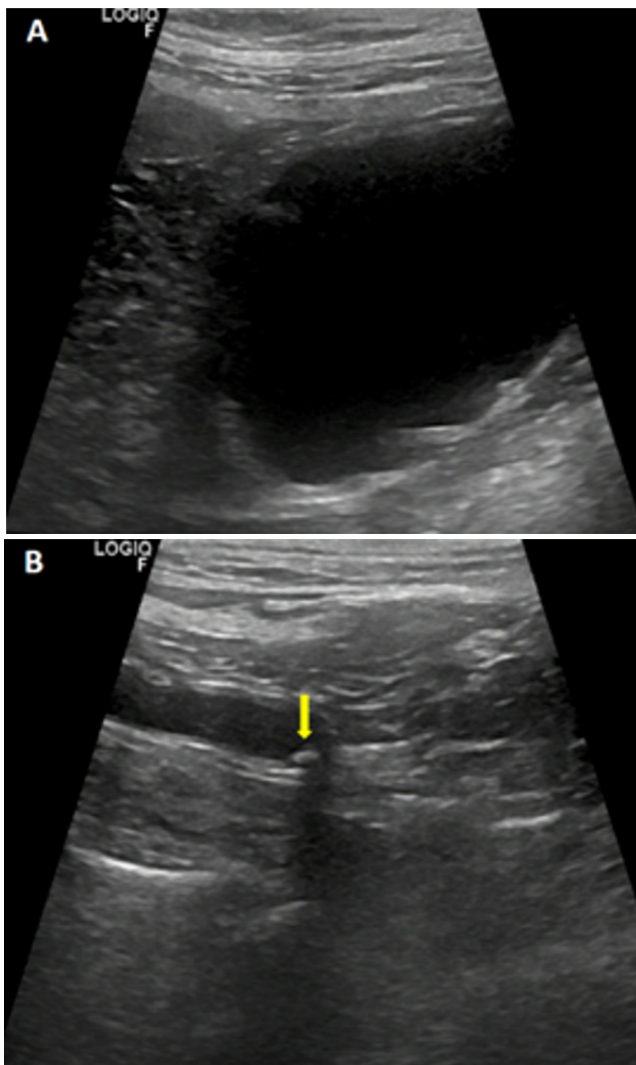


Figure 1. Renal and ureteral ultrasound of a dog with hydronephrosis, ureterolithiasis, and ureteral torsion. A) Loss of normal ultrasound pattern, severe thinning of the cortex and accumulation of anechogenic content. B) Severe dilation of the ureter, with the presence of an echogenic structure forming a 3mm posterior acoustic shading (arrow).

A second ultrasound examination was done once the patient fasted for eight hours. A hyperechogenic structure forming posterior acoustic shading was found (Figure 1B). The structure measured 3 mm in diameter, and it was located in the left ureter close to the bladder, which is compatible with ureterolithiasis. In addition, the presence of a diverticular structure in the posterior to the calculi was visible, suggesting ureteral torsion. When combined, all clinical and ultrasonographic findings suggested hydronephrosis due to ureteral obstruction, ureterolithiasis, and ureteral torsion. These findings were led to the therapeutical election of a unilateral nephrectomy.

Surgical procedure and postoperative treatment.

The patient underwent the exploratory laparotomy a day after the examination. No treatment was established previous to the surgery. Pre-anesthetic medication was performed with intramuscular application of methadone (0.3 mg/kg) and acepromazine (0.015 mg/kg). Anesthetic maintenance consisted of inhaled anesthesia with isoflurane in the concentration needed to maintain surgical plane, and continuous intravenous infusion of fentanyl (4 µg/kg/h) and lidocaine (1.5 mg/kg/h) for trans operative analgesia. In addition, at the beginning of the surgical procedure, cephalothin (30 mg/kg IV) and dipyrone (25 mg/kg IV) were used. The procedure occurred without complications, methadone (0.3 mg/kg SC) and meloxicam (0.1 mg/kg IV) were applied immediately post-procedure.

During the procedure, it was observed that the left ureter was enlarged (Figure 2) and with increased peristalsis. Hydronephrosis, ureterolithiasis, and ureteral torsion were identified, confirming the ultrasound findings. Left unilateral nephrectomy was performed as described by Ferro et al. (2018) (6). After the surgical procedure, the patient remained hospitalized for one day, receiving scopolamine (0.2 mg/kg IV q8h), dipyrone (25 mg/kg IV q8h), tramadol (2 mg/kg IV q8h), and amoxicillin with potassium clavulanate (12.5 mg/kg SC q12h). The same treatment was prescribed to be continued at home orally for another 10 days, and meloxicam was added (0.1 mg/kg). A medical visit was scheduled within 15 days for reassessment and a new blood profile analysis (Table 2).

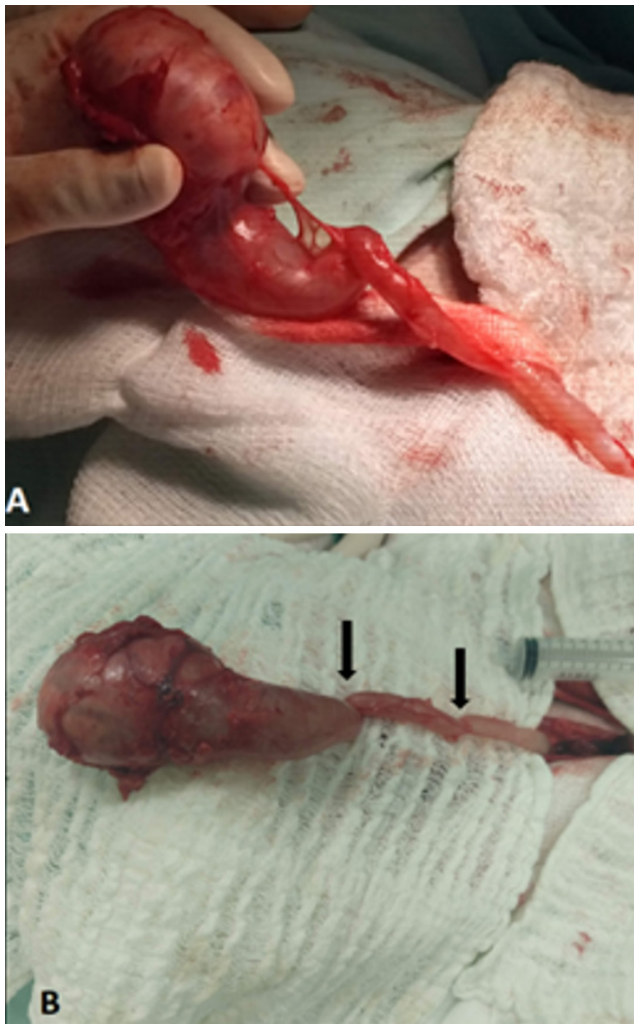


Figure 2. Trans-operative photograph of a dog diagnosed with hydronephrosis, ureterolithiasis, and ureteral torsion, confirmed by exploratory laparotomy. (A) Left kidney with significantly increased dimensions; (B) Torsion of the ureter in its proximal and medial portions to the kidney (arrows).

Table 2. Biochemical analyzes of a dog with ureterolithiasis and ureteral torsion without clinical symptoms 15 days after a left unilateral nephrectomy.

Biochemical	Result	Reference
Albumin (g/dL)	3.3	3.2 – 4.1
ALT (UI/L)	27.0	17.0 – 95.0
Creatinine (mg/dL)	1.1	0.6 – 1.4
Alkaline phosphatase (UI/L)	46.0	7.0 – 115.0
Total proteins (g/dL)	5.8	5.5 – 7.2
Urea (mg/dL)	25.0	9.0 – 26.0

ALT – alanine aminotransferase.

Post-operative return. Fifteen days after surgery, the owner reported that the patient was well and without any evidence of urinary tract changes. In addition, no changes were identified in the physical examination, complete blood count, or biochemical analysis. Therefore, the external surgical sutures were removed, and the patient was discharged. Investigation and treatment of breast cancer and otophematoma were recommended, but there was no return from the owner.

DISCUSSION

The present report provides unprecedented information on the diagnosis of ureteral torsion associated with ureterolithiasis and secondary hydronephrosis in a dog. These abnormalities were detected by conventional ultrasound and confirmed by exploratory laparotomy. To this date, no reports of canine ureteral torsion have been found in the literature.

Hydronephrosis is characterized by the dilation of the pelvis and renal calices (1). It occurs due to retrograde accumulation of urine in the kidney due to obstructive conditions, culminating in the destruction of the renal parenchyma (7). The obstruction can be acute or chronic, unilateral or bilateral, partial or total, promoting in most cases dilatation of the system upstream of the obstructive point, which facilitates urinary stasis and increases the risk of infection (8).

Among the etiologies of hydronephrosis, there is ureterolithiasis, which occurs when the urine is supersaturated by minerals, and with a decrease urination frequency (9). As in the case reported, the diagnostic of this condition can be done by ultrasound study by visualizing a hyperechogenic structure that forms an acoustic shadow in ureter topography (10). However, when the analysis of the ureteral calculus is not performed, the establishment of the specific type of ureterolithiasis is not possible, and this was a limitation in this case reported.

In addition to ureterolithiasis, a diverticular region was found in the posterior region of the stone, corresponding to torsion in that area. To the present date, no description of this condition was reported in the canine species. In humans, this condition is considered rare, and its etiology has not been established; nonetheless, it is believed that it may be associated with failures

in embryonic or fetal development (11). Still, torsion of ureters can occur in patients with congenital ureteral stenosis (12) or after inadequate surgical reimplantation of the ureter in cases of ectopic ureter (13). Considering that the patient had no history of urinary surgery, the torsion hypothesis secondary to ureteral reimplantation was ruled out. Since the patient was 9-years old, the congenital cause was considered less likely associated with this condition; however, this hypothesis cannot be ruled out since the hydronephrosis was asymptomatic, and there were no previous ultrasound exams done.

It was not possible to identify whether ureteral torsion was primary or secondary to lithiasis in the reported case. However, considering that urinary obstruction may increase the risk of infection (8) and that urinary infection facilitates the formation of ammonium urate stones (14), it is believed that the torsion may have occurred primarily. On the other hand, the hypothesis that the torsion was secondary to lithiasis is also considered, as it is known that obstructive cases of the ureters promote the retrograde accumulation of urine and, consequently, changes in the peristalsis of this organ (7).

Regardless of the origin, when hydronephrosis was identified, the priority was the treatment of this condition. Even though the patient did not have a history of urinary changes or even changes in blood biochemicals, it is known that this disease can promote renal injury, culminating in irreversible conditions or death (15). Thus, it was opted for exploratory laparotomy to confirm the ureteral torsion and then nephrectomy to remove the stone that was in the left ureter.

The ultrasonographic detection of these abnormalities was crucial for the management of clinical case. The therapy of renal injury was prioritized before the patient presented laboratory alterations or clinical signs.

This report demonstrated that, even without clinical presentation and laboratory exams alterations, the B-mode ultrasonography allowed the ureteral torsion and secondary hydronephrosis identification. This way, it was possible to establish the appropriate therapy promptly and prevent disease progression and development of clinical symptoms.

REFERENCES

1. Lam NK, Berent AC, Weisse CW, et al. Endoscopic placement of ureteral stents for treatment of congenital bilateral ureteral stenosis in a dog. *J Am Vet Med Assoc*. 2012; 240(8):983-990. <https://doi.org/10.2460/javma.240.8.983>
2. Hemal AK, Nayyar R, Gupta NP, Dorairajan LN. Experience with robotic assisted laparoscopic surgery in upper tract urolithiasis. *Can J Urol*. 2010; 17(4):5299-5305. <https://www.canjurol.com/abstract.php?ArticleID=&version=1.0&PMID=20735910>
3. Berent AC, Weisse C, Mayhew PD, et al. Evaluation of cystoscopic-guided laser ablation of intramural ectopic ureters in female dogs. *JAVMA*. 2012; 240(6):716-725. <https://doi.org/10.2460/javma.240.6.716>
4. Ricciardi M, Campanella A, Martino R. Computed tomographic features of urinary bladder torsion in two dogs. *J Small Anim Pract*. 2018; 59(3):188-195. <https://doi.org/10.1111/jsap.12694>
5. Hughes JR, Johnson VS, Genain MA. CT characteristics of primary splenic torsion in eight dogs. *Vet Radiol Ultrasound*. 2020; 61(3):261-268. <https://doi.org/10.1111/vru.12844>
6. Ferro SL, Jönck F, Cardoso E, et al. Nephrectomy in a Australian Cattle Dog parasitized by *Dioctophyma renale*. *Acta Sci Vet*. 2018; 46(1):1-6. <https://doi.org/10.22456/1679-9216.85151>

7. Cardoso KMMC, Souza IP, Silva CIF, et al. Bilateral Primary Obstructive Giant Megaureter in an Adult Dog. J Comp Pathol. 2019; 170:101-104. <https://doi.org/10.1016/j.jcpa.2019.06.004>
8. Tucci JR, Cologna AJ, Suaid HJ, et al. Ureterocystoplasty in rats. Acta Cir Bras. 2000; 15(2):43-46. <https://doi.org/10.1590/S0102-86502000000600013>
9. Rick GW, Conrad MLH, Vargas RM, et al. Urolitíase em cães e gatos. Pubvet. 2017; 11(7):646-743. <https://www.pubvet.com.br/artigo/3927/urolitiacutase-em-catildees-e-gatos>
10. Arjentina IGPY. PUTRININGSIH, P.A.S. Problems detection in urinary tract of dogs using ultrasound method. Braz J Vet Res An Sci. 2017; 1(2):43-46. <https://doi.org/10.24843/JVAS>
11. Ostling K. The genesis of hydronephrosis. Acta Chir Scand. 1942; 86:72.
12. Berry JV. Bilateral torsion of the ureter: case report and brief review of the literature. J Urol. 1938; 40(3):378-383. [https://doi.org/10.1016/S0022-5347\(17\)71777-6](https://doi.org/10.1016/S0022-5347(17)71777-6)
13. Palestrant AM, Dewolf WC. The pseudostricture of transplant ureteral torsion. Radiology. 1982; 145:49-50. <https://doi.org/10.1148/radiology.145.1.6750687>
14. Tion MT, Dvorska J, Saganuwan SA. A review on urolithiasis in dogs and cats. Bulg J Vet Med. 2015; 18:1-18. <https://doi.org/10.15547/bjvm.806>
15. Castro PF, Matera JM. Ureterolitíases obstrutivas em cães: avaliação da função renal na indicação da ureterotomia ou ureteronefrectomia. MVZ do CRMV-SP. 2005; 8:38-47. <https://doi.org/10.36440/recmvz.v8i1.3176>