



Ultrasonographic detection of meningoencephalitis in a dog

Marcus Antônio Rossi Feliciano^{1,2} ; Rafael Kretzer Carneiro¹ ; Igor Cezar Kniphoff da Cruz^{1*} ; Tainara Moraes Pereira² ; Ricardo Pozzobon² ; Angel Ripplinger² ; Alexandre Mazzanti² ; Camila Lie Yamauchi² ; Denise Jaques Ramos² ; Laura Magalhães Ribeiro² .

¹Universidade Estadual Paulista "Júlio de Mesquita Filho", Faculdade de Ciências Agrárias e Veterinárias, Departamento de Cirurgia, Jaboticabal, Brazil.

²Universidade Federal de Santa Maria, Cidade Universitária, Santa Maria, Brazil.

*Correspondence: igor_113@hotmail.com

Received: November 2020; Accepted: May 2021; Published: July 2021.

ABSTRACT

The aim of this report is to disseminate ultrasound findings of meningoencephalitis in a dog, diagnosed by analysis of cerebrospinal fluid collected by guided-ultrasound puncture. The patient presented walking in circles, absence of bilateral threat reflex, decreased left eyelid reflex, divergent strabismus of the right eye, negative nasal sensation on the right side, and an increase in volume of skullcap with the presence of open fontanelle. The clinical suspicion was hydrocephalus and/or inflammatory/infectious disease. The distemper rapid test was negative. The hematological profile showed an increase in alanine aminotransferase enzyme. Ultrasound examination was performed with patient in sternal decubitus, using a linear transducer (9.0 MHz). Images were obtained in longitudinal and transverse sections through the temporal windows and bregmatic fontanelle. The presence of a marked anechogenic content with moderate amount of floating hyperechogenic spots was observed, with retraction and increased echogenicity of the brain. Cerebrospinal fluid was collected using the bregmatic fontanelle for ultrasound-guided puncture, under general anesthesia. Meningoencephalitis was indicated by mononucleated cells and red blood cells founded in cerebrospinal fluid analysis. However, the patient not return to start treatment and investigate the cause of the meningoencephalitis.

Keywords: Neurology; disease; hydrocephalus; canine; imaging diagnostic (*Source: MeSH*).

RESUMEN

El objetivo de este relato es difundir los hallazgos ecográficos de meningoencefalitis en un perro, diagnosticado mediante análisis de líquido cefalorraquídeo colectado mediante punción guiada por ecografía. El paciente presentaba caminar en círculos, ausencia de reacción al reflejo de amenaza bilateral, disminución del reflejo palpebral izquierdo, estrabismo divergente del ojo derecho, sensación nasal negativa en el lado derecho y aumento de volumen de la región frontal del cráneo con presencia de fontanela abierta. La sospecha clínica fue hidrocefalia y/o enfermedad inflamatoria/infecciosa. La prueba rápida de moquillo fue negativa. El perfil hematológico mostró un aumento de la enzima alanina aminotransferasa. El examen ecográfico se realizó con el paciente en decúbito esternal,

How to cite (Vancouver).

Rossi MA, Kretzer CR, Kniphoff IC, Pereira T, Pozzobon R, Ripplinger A, et al. Ultrasonographic detection of meningoencephalitis in a dog. Rev MVZ Córdoba. 2021; 26(3):e2218. <https://doi.org/10.21897/rmvz.2218>



©The Author(s), Journal MVZ Córdoba 2021. This article is distributed under the terms of the Creative Commons Attribution 4.0 International License (<https://creativecommons.org/licenses/by-nc-sa/4.0/>), lets others remix, tweak, and build upon your work non-commercially, as long as they credit you and license their new creations under the identical terms.

utilizando un transductor lineal (9,0 MHz). Las imágenes se obtuvieron en cortes longitudinales y transversales a través de las ventanas temporales y fontanela bregmática. Se observó la presencia de un marcado contenido anecogénico con moderada cantidad de partículas hiperecogénicas flotantes, con retracción y aumento de la ecogenicidad del cerebro. El líquido cefalorraquídeo fue colectado utilizando la fontanela bregmática para una punción guiada por ecografía, bajo anestesia general. La meningoencefalitis fue identificada pues se encontraron células mononucleadas y glóbulos rojos en el análisis del líquido cefalorraquídeo. El paciente no regresó para iniciar el tratamiento e investigar la causa de la meningoencefalitis.

Palabras clave: Neurología; enfermedad; hidrocefalia; canino; diagnóstico por imagen (*Fuente: MeSH*).

INTRODUCTION

Meningoencephalitis in dogs may occur due to different processes, promoting behavioral changes and neurological symptoms, such as walking in circles, ataxia or seizures (1). The definitive diagnosis is made through histopathological examination, but it is possible to assume it based on the history, physical exam and complementary exams (analysis of cerebrospinal fluid and magnetic resonance), in addition to the exclusion of differential diagnoses (2).

Transcranial ultrasonography is commonly used to identify ventriculomegaly and hydrocephalus in veterinary medicine (3). Furthermore, it allows the evaluation of cerebrospinal fluid, which presents an anechoic and homogeneous aspect when normal (4).

This technique was initially described with access through the bregmatic fontanelle, even in adult dogs, allowing partial assessment of brain tissue; however, currently, other accesses were used to complement the study, such as the occipital, temporal and foramen magnum (5). Although it allows assessment of brain tissue, no description of ultrasound findings in dogs with meningoencephalitis has been found in the literature, magnetic resonance imaging was the preferred exam for identifying this alteration (6), however, even though magnetic resonance imaging is more accurate for brain tissue evaluation, it has low availability in the veterinary routine in several countries.

The collection of biological material guided by ultrasound is often performed in veterinary medicine, this technique may reduce trans and post-procedure complications and improve the quality of the material obtained (7). However, there are no reports of cerebrospinal fluid collection through ultrasound-guided bregmatic fontanelle puncture, both in humans and animals.

In view of the low availability of studies demonstrating the applicability of transcranial ultrasonography in dogs, the present report aimed to describe the ultrasound findings obtained during the evaluation of a dog with hydrocephalus and neurological signs of meningoencephalitis. In addition, the technique of intracranial cerebrospinal fluid collection, guided by ultrasound, which has not yet been described in veterinary medicine.

PATIENT EVALUATION

Anamnesis. A three year not neutered Chihuahua bitch was presented for consultation with the main complaint of walking in circles (clockwise). According to the owner, the patient always presented agitated behavior and in the past week, she had started with difficulty in apprehending food, lack of appetite, decreased water intake, dysuria, dyskinesia, difficulty in walking and pressing her head against objects. The owner did not have accurate information concerning of animal's vaccination history.

Clinical examination findings. After anamnesis, the patient underwent general and neurological physical examinations, and the walking in circles symptom (clockwise - to the right) was observed, however without changes in postural reactions. The state of consciousness was alert and the head was tilted to the right. There was an absence of reaction to bilateral threat reflex and a decrease in the left eyelid reflex, divergent strabismus of the right eye at rest, a negative nasal sensation on the right side and an increase in the volume of the skullcap, with the presence of an open fontanelle.

Clinical suspicion. Considering the history and findings, congenital malformation (hydrocephalus), non-infectious inflammatory disease (meningoencephalitis of unknown or granulomatous cause) or infectious (distemper, neosporosis or toxoplasmosis) was suspected.

Laboratorial exams. To assist the diagnosis, complementary tests were requested: hematological profile (complete blood count and biochemicals - albumin, alanine aminotransferase, creatinine, alkaline phosphatase, total proteins and urea), rapid distemper test for antigen detection and intracranial ultrasound.

There were no abnormalities in the blood count, albumin, creatinine, urea and alkaline phosphatase values, however there was an increase in the value of alanine aminotransferase (144.0 IU / l - reference: 6.0 to 83.0 IU / l). The result of the rapid test for distemper was negative.

Ultrasonographic exam. It was decided to perform transcranial ultrasonography because it is a fast, non-invasive and low-cost examination, in addition to the fact that other more accurate techniques are not available, such as computed tomography and magnetic resonance imaging. The ultrasound examination was performed using a General Electric LOGIQ F6 device (GE Healthcare, California, United States) and a multifrequency (5.0 - 13.0 MHz) linear transducer in a frequency of 9.0 MHz; through the temporal and the bregmatic fontanelle windows, scanning in longitudinal and transversal sections. Through this examination, the presence of ventriculomegaly, with marked accumulation of anechogenic content, and evident hyperechogenic points (suggestive of cellular debris), with retraction and increased echogenicity of the brain parenchyma was seen (Figure 1). It was then suggested the transcranial collection of cerebrospinal fluid liquid, guided by ultrasound percutaneous puncture, for further analysis of the material.

Cerebrospinal fluid collection and analysis.

To collect the cerebrospinal fluid, the animal was submitted to general anesthesia using tramadol hydrochloride (3mg / kg / IV), diazepam (0.15mg / kg / IV) and propofol (5mg / kg / IV), there is no need for reapplication of anesthetic agents. Subsequently, trichotomy and antiseptics of the skullcap was performed (in bregmatic fontanelle topography) and the animal was kept in the right lateral decubitus position, with the probe positioned under the fontanelle window, in a longitudinal position to the patient's sagittal plane. After the identification of the best place to collect the material (region with the largest amount of liquid and small presence of brain tissue), a 22G x 38mm spinal needle

was inserted percutaneous and transcranial, parallel and adjacent to the probe, until visible on ultrasound, and 1.5 ml of the material was collected for further analysis (Figure 2).

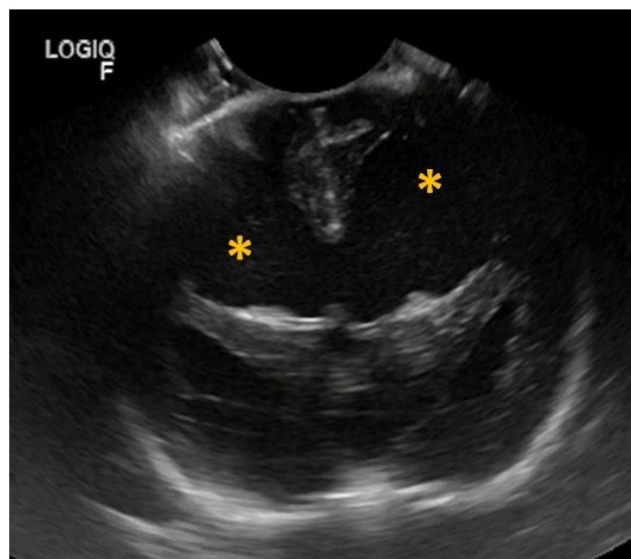


Figure 1. Transcranial ultrasonography performed through bregmatic fontanelle in a dog with hydrocephalus and meningoencephalitis. Note the presence of ventriculomegaly, anechoic content with floating hyperechogenic points (asterisc).

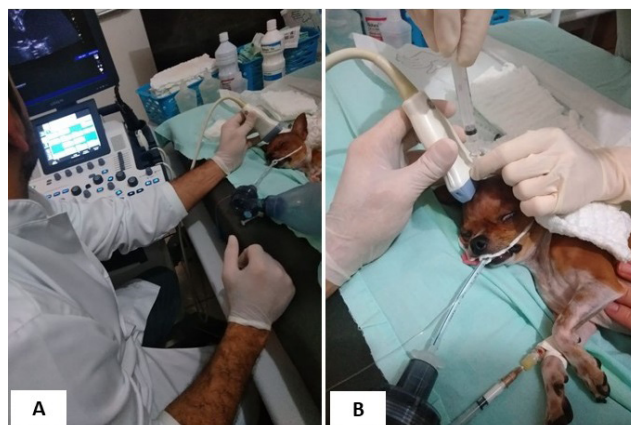

Figure 2. Collection of cerebrospinal fluid through bregmatic fontanelle in a dog with hydrocephalus and meningoencephalitis. (A) Ultrasound to determinate the best region to collection. (B) collection the material by spinal needle puncture.

The liquid was colorless, with a clear appearance, density of 1006, pH 8.0, proteins 110.0 mg/dL, glucose 6.7 mg/dL and with the presence of occult blood. Cytology demonstrated the presence of mononucleated cells (8.8 cells/mm³) and a slight amount of red blood cells, indicating the presence of meningoencephalitis.

Diagnosis. By associating the patient's history, findings from physical, neurological, ultrasound examinations and the results of cerebrospinal fluid evaluation, the animal was diagnosed with hydrocephalus and meningoencephalitis of unknown origin. Therapy was not instituted, because the owner did not return with the patient after exam results and did not contact to provide more information on the evolution of the patient's condition.

DISCUSSION

In this report, we describe a case of hydrocephalus associated with meningoencephalitis of unknown cause in a dog. The diagnostic suspicion was based on clinical, transcranial ultrasound findings and supported by the cerebrospinal fluid (CSF) analysis collected by guided ultrasound puncture through the bregmatic fontanelle. The definitive diagnosis of meningoencephalitis in small animals is obtained through post-mortem histopathological analysis (2), but this report brings important findings that indicate the possibility of using ultrasound in screening and diagnosing these conditions.

The patient's neurological signs were consistent with changes in the central nervous system, however, infectious, non-infectious and neoplastic inflammatory disorders are similar in clinical presentation. Therefore, the presumptive diagnosis of meningoencephalitis is based on imaging tests (magnetic resonance imaging), serological tests for infectious diseases and CSF analysis (6). In addition, the lack of a clinical history did not make it possible to determine the primary cause of hydrocephalus since, as described in medicine, an inflammatory process in the meninges or ventricles can secondarily lead to hydrocephalus (8). On the other hand, the primary hydrocephalus is more frequent in veterinary medicine (9), with a higher prevalence in toy breeds, such as Chihuahuas (6).

The ultrasound evaluation of the brain through the foramen magnum, temporal (5) and open bregmatic fontanelles windows (3) brings relevant brain information of macroscopic anatomy in small animals (5). In this context, the ultrasonography was extremely important for diagnostic complementation, since it allowed the evaluation of brain structures and cerebrospinal fluid by longitudinal and transversal scans, both through the bregmatic fontanelle and through the front windows.

Ultrasonography makes an effective contribution to the diagnosis of hydrocephalus in cats (3) and can identify changes in human fetuses as early as 18 to 20 weeks of gestation (10). The ultrasound findings are based on the visualization of marked ventricular increase with anechogenic content (4). Other imaging tests such as computed tomography and magnetic resonance imaging can assist in the diagnosis (11), but in this report, brain evaluation using ultrasound made it possible to find changes consistent with literature that contributed to the diagnostic screening of the disease without the need for more advanced and invasive exams. In addition, ultrasound proved to be a painless, quick and did not require the use of drugs to contain the patient.

The presence of atrophy and increased echogenicity of the cerebral parenchyma observed in the imaging exam are consistent with brain inflammation in dogs (12). Also, the presence of hyperechogenic dots observed in the CSF may be due to the increase in the amount of mononucleated cells identified in cytology. According to Mariani *et al.* (2019), the increase CSF protein and mononuclear cells suggests an inflammatory disorder in the central nervous system and even though no increase in glucose level was observed in the reported case, the patient was diagnosed with meningoencephalitis by the association of the increased mononucleated cells with transcranial ultrasound changes.

CSF collection can be performed by the cerebellomedullary cistern and lumbar subarachnoid space in dogs (11) but obtaining by the cistern can be a risky procedure in the absence of information on caudal cerebellar hernia or other abnormalities (4). In this report, ultrasonography presented a satisfactory assessment of the cerebral ventricle, but it did not allow to inform about other changes. Thus, we chose to the guided collection procedure of CSF directly through the bregmatic fontanelle, which made it possible to collect enough volume to identify changes that contributed to the diagnosis. Besides that, it proved to be a safe approach, with no complications during or after the procedure.

In some cases, the cerebrospinal fluid can be collected directly from the enlarged ventricles (4), however there were no descriptions of the technique or reports in dogs undergoing this procedure in an ultrasound-guided puncture.

The transcranial ultrasound examination made it possible to diagnose ventriculomegaly compatible with hydrocephalus and suggested the presence of an inflammatory condition, indicating and assisting the collection of cerebrospinal fluid. Through ultrasound findings and CSF analysis, it was possible to diagnose meningoencephalitis of unknown origin in the evaluated canine.

Conflict of interest

The authors declare no conflicts of interest.

REFERENCES

- Zamboni R, Scheid HV, Alberti TS, Marcolongo-Pereira C, Schild ALP, Raffi MB, et al. Encefalite do cão Pug no Sul do Brasil. *Sci Anim Health*. 2018; 6(3):256-265. <https://doi.org/10.15210/sah.v6i3.13209>
- Alves L, Barbosa J, Costa PPC. Meningoencefalite necrosante (MEN). *J Vet Sc Public Health*. 2016; 3(1):23-29. <https://doi.org/10.4025/revcivet.v3i1.32566>
- Marinho CP, Bacha FB, Santos GA, Braz PH. Hidrocefalia congênita bilateral total em felino: relato de caso. *Arq Bras Med Vet Zootec*. 2018; 70(6):1911-1915. <https://doi.org/10.1590/1678-4162-10363>
- Thomas WB. Hydrocephalus in Dogs and Cats. *Vet Clin North Am Small Anim Pract*. 2010; 40(1):143-159. <https://doi.org/10.1016/j.cvsm.2009.09.008>
- Cintra TCF, Carvalho CF, Canola JC, Nepomuceno AC. Transcranial ultrasonography in healthy dogs: technique standardization and anatomic description. *Arq Bras Med Vet Zootec*. 2014; 66(1):61-68. <https://doi.org/10.1016/j.ultrasmedbio.2013.02.365>
- Coates JR, Jeffery ND. Perspectives on meningoencephalomyelitis of unknown origin. *Vet Clin Small Anim Pract*. 2014; 44(6):1157-1185. <https://doi.org/10.1016/j.cvsm.2014.07.009>
- Manfredi S, Carvalho C, Fonti P, Gnudi G, Miduri F, Fabbi M, et al. Complications of ultrasound-guided cystocentesis in companion animals: 21 cases (2005-2016). *Turk J Vet Anim Sci*. 2018; 42(5):459-466. <https://doi.org/10.3906/vet-1802-11>
- Vitale V, Rossi E, Di Serafino M, Minelli R, Acampora C, Iacobelli F, et al. Pediatric encephalic ultrasonography: the essentials. *J Ultrasound*. 2018; 23:127-137. <https://doi.org/10.1007/s40477-018-0349-7>
- Coates JR, Axlund TW, Dewey CW, Smith J. Hydrocephalus in dogs and cats. *Compend Contin Educ Pract Vet*. 2006; 28:136-150. <https://doi.org/10.1016/j.cvsm.2009.09.008>
- Garne E, Loane M, Addor MC, Boyd PA, Barisic I, Dolk H. Congenital hydrocephalus-prevalence, prenatal diagnosis and outcome of pregnancy in four European regions. *Eur J Paediatr Neurol*. 2010; 14(2):150-155. <https://doi.org/10.1016/j.ejpn.2009.03.005>
- Mariani CL, Nye CJ, Tokarz DA, Green L, Lau J, Zidan N, et al. Cerebrospinal fluid lactate in dogs with inflammatory central nervous system disorders. *J Vet Intern Med*. 2019; 33(6):2701-2708. <https://doi.org/10.1111/jvim.15606>
- Carvalho CF, Perez RB, Chamas MC, Maiorka PC. Transcranial Doppler sonographic findings in granulomatous meningoencephalitis in small breed dogs. *Can Vet J*. 2012; 53(8):855-859. <https://www.ncbi.nlm.nih.gov/pmc/articles/PMC3398522/>